

Microfine glove and toe caps and their use in lymphoedema management

Gail Close

Gail Close, Clinical Manager, Haddenham Healthcare

Email: Gail@hadhealth.com

The use of compression has been recognized as one of the four cornerstones of lymphoedema management (British Lymphology Society, 1997) and it can be pivotal in the maintenance of the condition. Compression therapy requires motivation and perseverance from the patient in order to achieve long-term control of the swelling (Woods, 2007a). For patients that need to wear compression hosiery as part of their daily routine it is important that it fits correctly and, for some, in a colour that allows them to 'hide' the garment or at least blend in with their wardrobe. For Curtis (2006) her arm dominates her daily life with massage, moisturizing and wearing her compression garments. Manufacturers can look at fabrics and colours but will never be able to take away the change for the patient in his or her daily life. However, the experience can be made slightly easier with fabric and colour choice where possible.

Hand oedema

Hand oedema can develop as a result of congenital abnormality, trauma, surgery or radiotherapy to the lymphatics that supply the arm. There is no test that can determine when, if or how the arm will be affected by cancer treatment. In some cases, lymphoedema will be limited to the hand. When diagnosing hand lymphoedema, signs to look for are decreased visibility of the veins,

increased skin and subcutaneous thickness on palpation and pitting oedema (Stanton et al, 2006).

Hand oedema can result in psychological and physical difficulties for the patient. Grip can be affected and in some instances the patient may report altered sensation to the fingers and hand as a direct result of the pressure from oedema on the nerve endings. If the hand is also the dominant hand then it can lead to reduced independence and could have a significant impact on the patient's quality of life (Close, 2007). The physical effects of hand oedema can be considerable but body image needs to be considered. Patients may find that the limb becomes the focus in their life and often dominates their daily activities (Curtis, 2006; Woods, 2007b)

'It's a big nuisance that has quite an impact on many aspects of life' (39 year old patient with lymphoedema).

Compression garments

When lymphoedema is present in the hand/fingers and toes, a glove and toe caps can be added to the compression garments that a patient may already be wearing. In some situations, a glove can be worn as a standalone garment, but it is rare for toe caps to be worn without additional hosiery or compression bandaging. Without a glove, the hand and fingers can swell causing a loss of dexterity as previously mentioned. If toe caps are not applied to swollen toes, the skin can become thickened, lymphangiomas can form (secondary to swelling), skin can break down, fungal infections can develop and there can be a loss of toe movement.

All compression garments must adhere to certain standards and are classified into compression classes. The Microfine glove is produced to the RAL compression standard, commonly used in the UK in the treatment of lymphoedema. All standards follow the principle of graduated compression along the length of the limb, from the distal to the proximal end (Close, 2007). Microfine technology produces an extremely fine, conforming flat-knit compression glove. The finer feel of the fabric allows an increased level of dexterity with less bulk over fingers, and conforms well to movement. The level of compression is not compromised by the fineness of the fabric (Close, 2007).

When worn in conjunction with other compression garments, toe caps and gloves help to reduce limb swelling. However, compression is only one part of lymphoedema

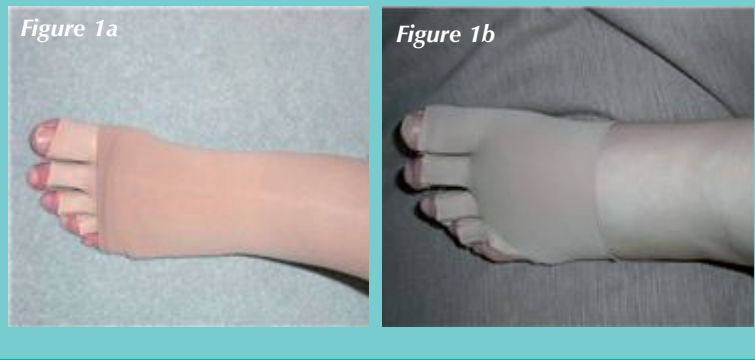
ABSTRACT

Lymphoedema garments have progressed in the last 10 years, so gone are the days when only one colour is available (that lovely beige!). How many patients would have to be persuaded to wear their compression hosiery in that desirable colour? Not just have the colours become more acceptable, so have the fabrics. There are a wide range of compression gloves available to the lymphoedema specialist to fit on the patient but that cannot be said of toe caps. The Microfine toe cap is the only one available as an off-the-shelf garment, and when the lymphoedema is deemed to be manageable in these garments, it offers an alternative to flat knit. The Microfine glove and Microfine toe cap are adaptable and can offer colour options and a fabric that is less bulky and fine. It also allows therapists to trim the length of each digit for a better fit without reducing compression. The author will present three case studies of patients that are using.

KEY WORDS

◆ Lymphoedema ◆ Compression ◆ Hand oedema

Case study 1. Mary



management, and the other cornerstones of lymphoedema management will always be advised to aid limb volume reduction.

Microfine toe caps and gloves

Microfine products are relatively new to the lymphoedema market. The Microfine glove was launched by Haddenham Healthcare Ltd in 2005 and the toe cap was launched in 2008. The Microfine technology enables the fingers to be cut without compromising the compression delivered. They will not fray or roll when cut. Their seams do not run when cut, unlike other compression garments. The Microfine glove allows the lymphoedema specialist to individually customize the garment, eliminating the need for custom-fit measuring in cases where finger length is the main concern. The toe caps are ultra thin and the fabric is smooth (Haddenham Healthcare, 2010). The measuring process is easy, as is the fitting. The glove and toe caps are available as off-the-shelf or custom-made products. Gloves are available in beige, sand and black; toe caps in sand and black. The gloves can be worn on either hand, and the toe caps on either foot (Close, 2007). Toe caps and gloves are also conveniently available on prescription tariff.

Toe caps are now being used widely in the community and by lymphoedema therapists as an alternative to toe bandaging, where possible. Toe bandaging is often difficult because toes are small and bandages slip with walking. They can be painful, cutting into toes, and in most cases come off completely. If compression bandaging continues without the toes being bandaged, they will become more swollen and skin breakdown can occur. With a toe cap applied underneath the bandaging, the toes are no longer forgotten. The main aim of compression is to ultimately

reduce limb volume and improve joint mobility and discomfort (Anderson et al, 2000).

This product focus is based on three case studies using either a Microfine glove or Microfine toe cap. The patients are women and have been using the garments for at least 6 months. They have all given their permission for the author to publish their information and photographs. Their confidentiality has been protected so each patient's name has been changed.

Case study 1. Mary

A 49 year old married lady with two children had a hysterectomy and bilateral inguinal node dissection in 1995 for a cervical carcinoma. Inguinal nodes were positive on the left and she underwent 4 weeks of radiotherapy and was prescribed hormone replacement therapy (HRT) after her surgery and continues with this. Incidentally she was never told that she might get lymphoedema. Other past medical history (PMH) includes bilateral hand arthritis.

Lymphoedema commenced in March 1996 with a small amount of oedema on the foot and ankle but settled overnight. Mary wore a tubigrip to help when the swelling was uncomfortable. Over the next 8 years it slowly progressed into her upper leg and it was not until November 2004 that she found help from a registered private manual lymphatic drainage (MLD) therapist. On initial assessment she had mild lymphoedema extending from foot to thigh, a positive Stemmer's Sign and the toes were very swollen. Toe bandaging was applied, hosiery was supplied from a local orthotics team and MLD commenced. Two weeks later, the toe bandaging had been successful and Mary was taught to self-bandage her toes. She remained fairly stable for 2 years. Following the death of her father in 2006, her leg worsened after helping her mother. A course of complex decongestive therapy (CDT) was given by the MLD therapist. This gave her a 6% reduction in total volume. Her hosiery was still managed by orthotics, however, she was given the incorrect garments. Mary had to pay privately for her hosiery in the end, as she just could not wait for another appointment. In 2007 further surgery was performed to her right inguinal nodes and an unknown number were removed; the reason why was never clear to her. This further increased her risk of lymphoedema in the right leg. It was only in 2008 that she was referred to a lymphoedema nurse specialist (LNS)

Initial appointment in April 2008

Mary was fully assessed, she had a moderate lymphoedema of 25% in the left leg, some swelling over the area of her bilateral inguinal dissections and the left calf was fibrosed in places. There was a risk of lymphoedema in the right leg. As no pre-surgery volumes had been recorded, the right leg was showing no visible signs of lymphoedema. Mary was fitted with a Class 3 thigh length compression garment for the left leg (*Figure 1a*) combined with a Microfine toe cap, trimmed to fit (*Figure 1b*). The little toe in the toe cap was removed as it did not tolerate compression,

Table 1. Size selector for off-the-shelf Microfine toe caps. Haddenham Healthcare

Circumference of palm at ball of foot	Size	PIP Code
21-23cm	X Small	347-9649
23-25cm	Small	347-9656
25-27cm	Medium	347-9664
27-29cm	Large	347-9672

becoming very painful. Mary said they felt strange to start with but she soon forgot about them. The LNS also fitted a compression ankle as the ankle was fibrotic. Owing to swelling in the inguinal region and upper thigh, compression pants were also supplied. The LNS gave her a donning aid to aid application of hosiery due to her hand arthritis. This was also combined with Mary performing simple lymphatic drainage (SLD) daily and she was having MLD twice monthly with a private MLD therapist. At her review appointment in June 2008, her leg reduced to 18% and her ankle was softer, as were her toes. Her Microfine toe cap was reduced by one size, to X-small (see *Table 1*), and her other garments were also reduced by one size.

In 2009 Mary had an episode of cellulitis, which fortunately only caused a minimal increase due to prompt action. Later in the year, the right leg showed signs of lymphoedema with some slight pitting around the ankle. This was as result of a long walk while on holiday but it settled overnight, so it was mutually agreed that observations would be made. In 2010 Mary is managed with Class 3 thigh length compression garments, Microfine toe caps, a compression anklet when needed, Class 2 compression pants and she has private MLD at 6-weekly intervals. This is her current maintenance programme.

Case study 2. Claire

A 52 year old lady was diagnosed with bilateral breast cancer in April 2008. She had bilateral wide local excisions (WLE) with axillary node sampling on the right and axillary node clearance on the left. This was followed with chemotherapy and bilateral breast radiotherapy. There was no other medical history of note.

Unfortunately, Claire developed mild left arm lymphoedema 7 months after surgery, prior to her radiotherapy. It was important to keep lymphoedema to a minimum. She is dominantly left-handed and her baseline measurements were taken prior to surgery and the baseline arm percentage was 3.1% greater on the right arm prior to surgery. The significance of this is that when her lymphoedema started in her left arm it was 10% larger than the contralateral limb. There was good limb function but very low self-esteem, anxiety and fear of her lymphoedema worsening. These symptoms are very common after going through breast cancer treatment and it was important to help her through the symptoms as this would ultimately help her to self-manage her lymphoedema. The LNS fitted Claire with a compression sleeve, taught her SLD and arranged some MLD prior to her radiotherapy.

In early 2009 CDT took place; Claire had 12 treatments and her arm reduced back to its pre-operative baseline measurements. Her self-esteem was improving as was her anxiety. She needed flat knit garments initially to maintain the loss but after 4 months of maintenance she was very keen to have a softer sleeve and glove. Having managed her anxiety very well up to this point, it was important for her to know that the LNS and her team were hoping that she would be able to wear her garments as and when needed,

Case study 2. Claire

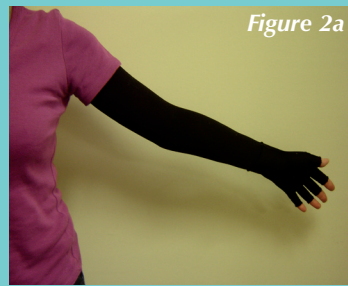


Figure 2a



Figure 2b




Figure 2c

i.e. gardening, housework etc. We fitted her with a Microfine glove (See *Table 2*) and compression sleeve (See *Figure 2c*), her self-confidence increased and she became more confident with managing her lymphoedema. Regaining dexterity was important to Claire as she was hoping to return back to work. The Microfine glove offered her this; in time she may be glove free.

In November 2009 she developed lymphoedema in her right arm, so she now wears bilateral garments (See *Figure 2b*). Surprisingly, she chose to have black garments as it 'made a statement' (*Figure 2a*). Claire has a choice of two colours of the three that are available for the Microfine glove (sand, beige or black). She is now very confident with her lymphoedema management, with high self-esteem and self-confidence. Hosiery has played a huge part in her journey so far, and she continues to have private MLD on a 2-monthly basis as maintenance.

Case study 3. Anne

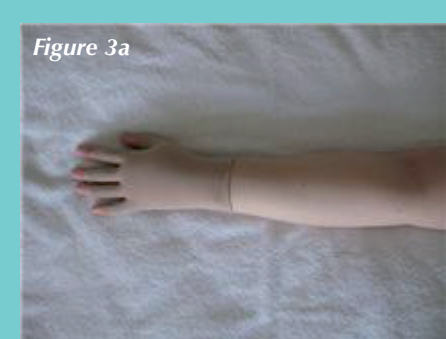

Figure 3a

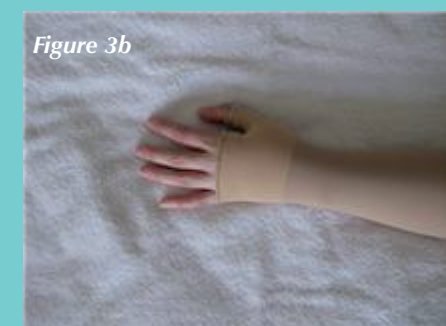

Figure 3b



Figure 3c

Table 2. Size selector for off-the-shelf Microfine gloves. Haddenham Health Care

Measurement points	Xsmall-1	Small-2	Medium-3	Large-4
Palm at Base of fingers	Below 18cm	18-20cm	20-22cm	Over 22nd
Palm at fold of the thumb	Below 19cm	19-21cm	21-23cm	Over 24cm
Wrist	Below 18cm	18-20cm	20-22cm	over 22cm

Case study 3. Anne

A 39 year old lady, who was diagnosed with breast cancer in January 2009 and underwent a mastectomy with immediate reconstruction in February, Anne developed cellulitis post-operatively. She received a course of adjuvant chemotherapy, which was completed in June 2009. Her lymphoedema commenced in September 2009 following an episode of cellulitis on the breast. A full lymphoedema assessment was performed. Treatment options were discussed with her, a compression sleeve was applied with additional kinesio taping to the hand, and she was taught SLD. In November 2009, lymphoedema management for her hand was changed to a Microfine glove (*Figure 3a*). Within a few weeks the hand improved with wearing the glove and her breast was less painful with weekly MLD.

In December 2009 the breast implant was replaced. Following surgery, the left arm and hand increased to 18.1% and CDT was planned because of this increase. After CDT the arm reduced to 5% and she wore flat knit garments for a couple of months. She also started to increase her exercise tolerance by swimming twice weekly. Anne now wears a Microfine glove and compression sleeve (see *Figure 3b* and *3c*) as maintenance and is able to remove her garments for special occasions. She continues to have monthly MLD. The lymphoedema management in this final case study, although complicated by the cellulitis, was straightforward:

'I no longer find it socially awkward to walk around with the sleeve. When people ask what I've done to my arm, which complete strangers do surprisingly often, I tell them it's a swelling as a result from surgery and a nuisance rather than something terrible'

KEY POINTS

- ◆ Microfine toe caps can be considered when thinking about carrying out compression bandaging in the hospital/community.
- ◆ Don't dismiss hand lymphoedema. Early management does make a difference.
- ◆ Where possible allow patients a colour option if it helps them to wear the garments.
- ◆ The ability to adapt the length of the digits in the garments is very helpful in lymphoedema management.

Supporting the patient

Patient concordance is paramount in lymphoedema management as ultimately the patient has to be in charge of their every day management. All three patients in the case studies were concordant with their treatment and would try anything to reduce the lymphoedema. Hosiery plays a big part of this; it has to fit correctly in size and length, the patient must be able to apply their garments and of course remove them. The latter is not always checked though, so patients can be left until someone is available to remove it. Aids are available to help in the application of the garment, and also to remove them.

Conclusion

Microfine gloves and toe caps are ambidextrous so save valuable space on the shelves of lymphoedema clinics. The Microfine glove gives the therapist another option in the treatment of lymphoedema as it can be tailored to meet the individuals' needs. In times when costs need to be reduced, it gives an alternative to custom-made garments as the finger/toe length can be trimmed to fit. Patients in the case studies found the gloves comfortable and allowed them to manage their activities of daily living. The toe caps came into the market 3 years later; they have allowed patients more flexibility with foot wear as they are ultra thin and smooth (Haddenham Healthcare, 2010). This has been helpful for patients and it has also allowed some to wear flip-flops with their toe caps.

BJCN

Acknowledgement

The author would like to thank Carol-Ann Cahill for her contribution to this article.

Anderson L, Højris I, Erlandsen M, Anderson J (2000) Treatment of breast cancer-related lymphedema with or without manual lymphatic drainage. *Acta Oncologica* **39**(3): 399-405

British Lymphology Society (1997) *Strategy for lymphoedema care*. BLS Publications, Caterham

Close G (2007) The Microfine glove and its use in the management of hand oedema. *Journal of Lymphoedema* **2**(2): 70-75

Curtis L (2006) More than 'a bit of swelling' living with lymphoedema. *Journal of Lymphoedema* **1**(1): 72

Haddenham Health Care (2005) Haddenham Micro fine Toe Cap. [Product information leaflet].

Stanton A, Modi S, Mellor R, Levick R, Mortimer P (2006) Diagnosing breast cancer-related lymphoedema in the arm. *Journal of Lymphoedema* **1**(1): 12

Woods M (2007a) 'The role of compression therapy in the management of lymphoedema'. In: Woods M. *Lymphoedema Care*. Blackwell Publishing Ltd, Oxford: 111-130

Woods M (2007b) 'Living with lymphoedema'. In: Woods M. *Lymphoedema Care*. Blackwell publishing Ltd, Oxford: 143-153



Haddenham Healthcare

Problem Solving Compression Therapy



Microfine TOE CAPS

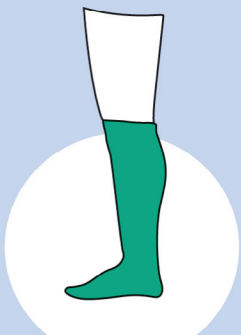
- Easy to Measure
- Easy to Fit

An off-the-shelf solution in the effective management of foot oedema. For use with open or closed compression hosiery and under bandaging.
No need to bandage toes!


Try our Pip Code Finder at:
www.hadhealth.com

Available on
Prescription

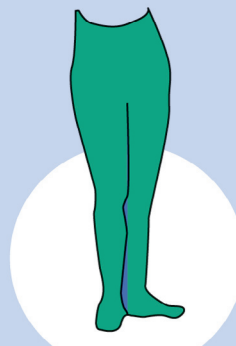
Haddenham Veni
More Choice Better Compliance



**BELOW KNEE
Veni**



**THIGH HIGH
Veni**



**TIGHTS
Veni**

Class 1 - 18-21mmHg

Class 2 - 23-32mmHg

Class 3 - 34-46mmHg

- Soft and stretchy
- Easy to apply
- Medically effective
- Aesthetically pleasing
- Optimum patient comfort

- 3 x RAL Compression Classes
- Sizes I-VIII plus Extra Wide
- 3 x Leg Lengths
- Colours Beige or Black
- Open or Closed Toe



www.hadhealth.com



01844 208842



sales@hadhealth.com

Haddenham Healthcare Ltd, Crendon House, Crendon Industrial Park, Long Crendon, HP18 9BB

